

# MANAGEMENT OF TRAUMATIC NAIL GUN INJURY TO CRANIUM, THORAX AND ABDOMEN: A CASE REPORT AND LITERATURE REVIEW

**Lim CH<sup>1</sup>, Gayathiri, G<sup>1</sup>, Chen SA<sup>1</sup>, Henry TCL<sup>1</sup>, Huei TJ<sup>1</sup>, Yuzaidi M<sup>1</sup>, and Rizal IA<sup>1</sup>.**

<sup>1</sup>Trauma Surgery Unit, Department of Surgery, Hospital Sultanah Aminah, Johor Bahru, Malaysia

## **Correspondence:**

Henry Tan Chor Lip,  
MMed Surg (UKM),  
General Surgeon, Trauma Surgery Unit,  
Department of General Surgery,  
Hospital Sultanah Aminah, Johor Bahru, Malaysia  
Email: rels1402@gmail.com  
Tel: +60137125014

## **Abstract**

Trivial nail gun injury accounts for an estimated 37 000 clinic and emergency room visits per year. Majority of these superficial nail-gun associated injuries can be treated as an office procedure with local anesthesia. However, cases of deliberate harm and multiple deep penetrating wounds with suspicion of injury to vital organs requires a multidisciplinary team approach. We present a case of deliberate self-harm using an industrial grade nail gun with multiple body site penetration. Outline of the initial assessment, multidisciplinary team management, treatment and patient outcomes are discussed in this case report. Outcomes of nail gun injury vary according to the type, length of nail and site of injury. From literature review, most nail-gun injures had neurological sequelae post treatment. Successful nail removal often is a multidisciplinary team effort with the component of psychiatric evaluation and treatment to prevent further future self-inflicted injuries.

**Keywords:** Nail Gun Injury, Self-Infliction, Cranium, Abdomen, Spine

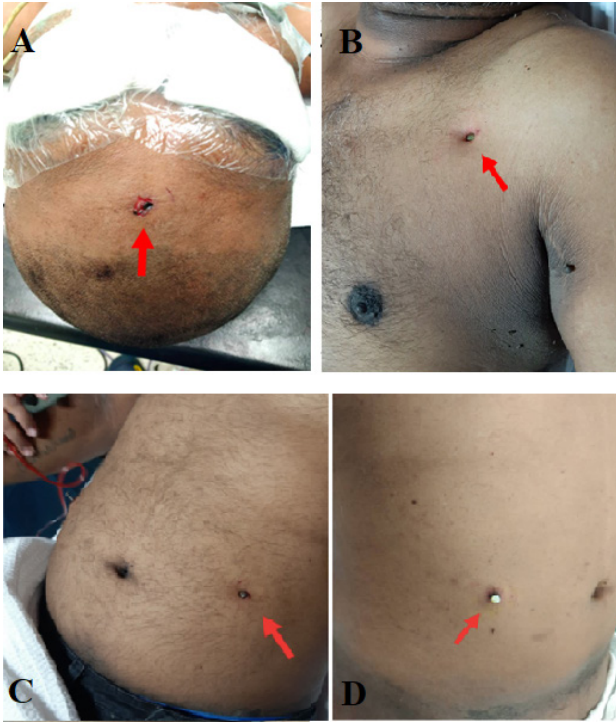
## **Introduction**

Nail guns first came into commercial use since the 1950s (1). The invention of the nail gun has brought convenience when it is widely used for quick fastening of furniture and heavy-duty objects. However, an increasing number of its associated injuries have been reported since its advent. Nail gun injuries includes have involved the cranium, thorax, spine, abdomen, upper and lower limbs (2-7). The energy produced by a nail gun could be comparable to a regular firearm as its projectile velocity may reach up to 100-150 m/s (330-490 ft/s) (2, 3). Nail gun injury is a leading cause of injury among carpenters and leads to approximately 37 000 emergency room visit per year (8). It is also pertinent to highlight that self-inflicted nail gun injury is underreported and its true incidence is unknown (4, 9). Self-inflicted nail gun injury often presents itself with an associated, underlying psychiatric disorders (9). Literature describing self-inflicted nail gun injury is scarce. This case report describes a gentleman who had allegedly attempted suicide by deliberate self-harm with a nail gun with multiple site penetration.

## **Case report**

A 47 years old man with no underlying medical illness presented to our Emergency Department with a traumatic nail gun injury to his forehead, chest and abdomen. Patient revealed that this was a deliberate act of self-injury due to multiple financial problems faced since the outbreak of COVID-19 infection in Malaysia. Further history revealed worsening of mood, insomnia and feeling worthless for the past 2 weeks.

Assessment at the emergency department revealed that the patient was fully conscious, had no neurological deficit and vital parameters was within normal limits. He was attended by the emergency, trauma surgery, neurosurgery and psychiatry teams. After psychiatric evaluation, the patient was diagnosed with major depressive disorder with suicidal intention. Upon examination, there was a small puncture wound over the left forehead with the nail head seen from the wound (Figure 1A). Lodged nails were also seen over the left anterior chest, axilla (Figure 1B) and bilateral abdominal wall (Figure 1C & D).

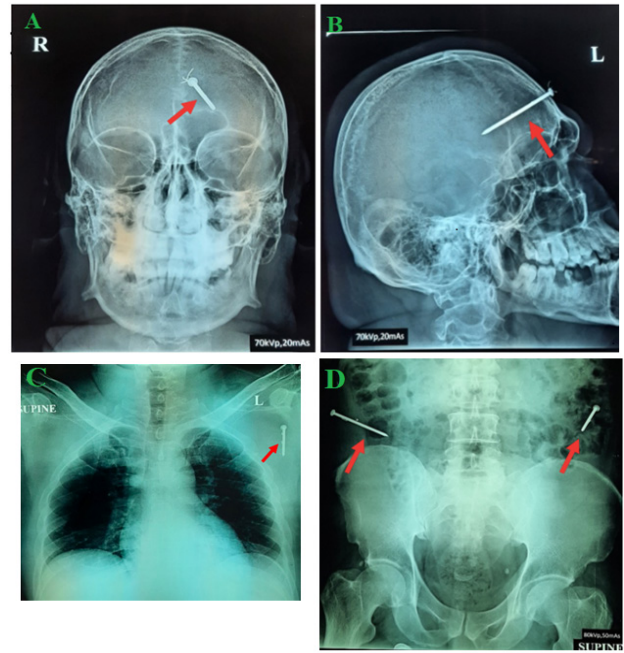


**Figure 1:** (A) Puncture wound over the forehead with minimal blood clots (B) Lodged nails over the left anterior chest wall in the axillary region (C) Nails over the bilateral abdominal wall left (D) right iliac fossa of the abdomen

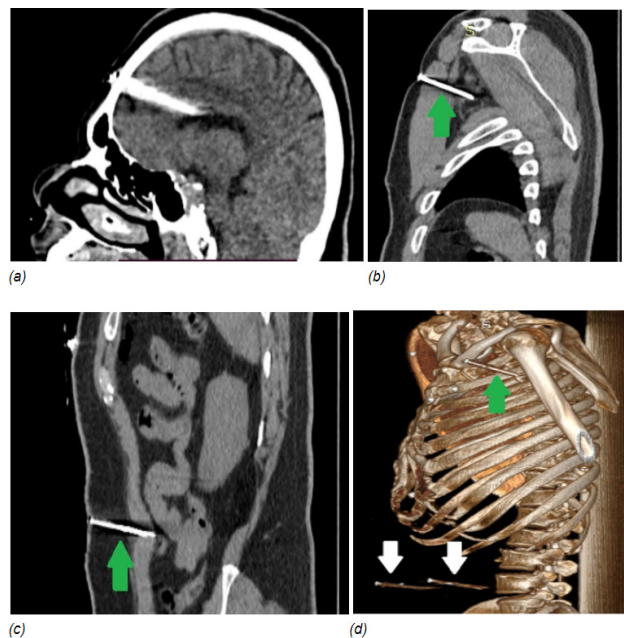
Radiograph of the skull revealed a single nail piercing directly into the frontal lobe of the skull (Figure 2A & 2B). Chest radiography revealed a single straight nail piercing into the left axillary without any pneumothorax (Figure 2C). Abdominal radiograph noted two deeply seated nail piercing into the abdominal wall at bilateral iliac fossa region respectively (Figure 2D).

Computerized tomography (CT) of the brain (Figure 3A & 3B) revealed that the nail was traversing the left frontal bone, corona radiata of the brain without any evidence of intracranial hemorrhage. Abdominal CT reports of foreign body lodged in bilateral iliac fossa with suspicious of peritoneal penetration (Figure 3C). Thoracic CT (3D) showed foreign body at the left axilla without any evidence of major vessel involvement.

From the radiographs and CT scan, the nail in the cranial vault appears to be in close proximity to the corona radiata. There were no significant surrounding hypodensities from the CT brain which suggests no bleeding from surrounding vessels. From the CT thorax, the nail trajectory only penetrated the pectoralis major and minor muscles without involvement of major vascular structures. However, from CT abdomen, there were high suspicion that the nail had penetrated the peritoneal cavity with overt bowel injury. Hence taking this into consideration, a craniotomy was performed to remove the nail (Figure 4A, 4B & 4C) under direct supervision. The nails were found to transverse the white matter – there was no overt bleeding upon removal.

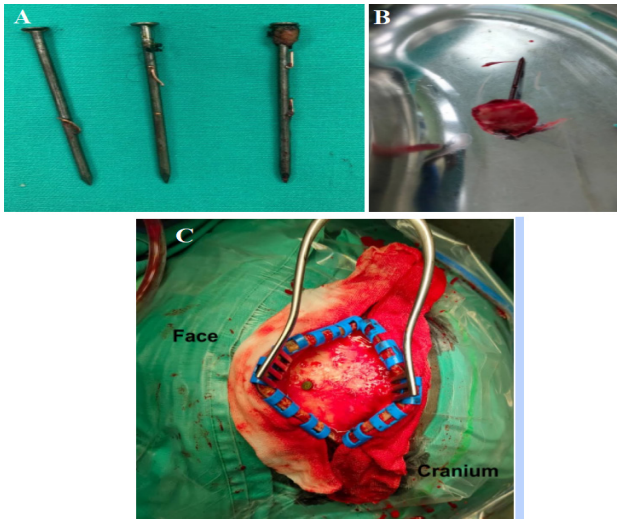


**Figure 2:** Skull radiograph (A) anteroposterior (B) lateral show a single nail piercing directly into the frontal lobe of the skull (C) Chest radiograph showed a nail piercing into the left axillary with no fracture, hemothorax or pneumothorax seen (D) Anterior posterior abdominal radiographs show two deeply seated nail (red arrows) piercing into the abdominal wall at bilateral iliac fossa region



**Figure 3:** Computed Tomography and sagittal view of the nails in (A) left frontal lobe of the brain, (B) left axilla, showing 6 cm long dense nail traversing through the left pectoralis major and minor to the left subclavian vein, (C) and (D), three-dimensional reconstructed image, shows two nails in the left and right lumbar region, in between the rectus and oblique muscles, with its distal tip within the muscles

Similarly, removal of the nail in the axilla under direct vision revealed no involvement of the subclavian and axillary artery. A laparotomy was performed to identify any perforation of the hollow viscous organs and allow direct examination of other solid intraperitoneal organs. This would allow direct inspection and immediate repair to any possible injured intraperitoneal organs. All nails (Figure 4A) were removed without complications. The laparotomy revealed no bowel injury. The nails removed were approximately seven centimeters long and half a centimeter in diameter.



**Figure 4:** (A) Three nails extracted from the axilla and abdomen and (B) one nail extracted from the left frontal lobe (C) Intraoperative nail extraction from the left frontal lobe

Post-operatively recovery was uneventful and the patient had full neurological function preserved. He was discharged on postoperative day two with further follow up in the psychiatry and neuro clinic. On follow-up at three months, it was noted that patient had started back working, with no neurologic deficits and is compliant to psychiatric treatment.

### Discussion

Nail guns are powerful industrial tools that are easy to operate and has increased the productivity of nailing tasks (8). However, the consequence of mishandling this device may lead to fatal injuries and morbidities (10). With increasing availability of nail guns for industrial use, its resulting injuries is increasing due to accidental or deliberate self-harm (9, 11). Common regions of injuries include the head, thorax, abdomen and extremities (2). The overall incidence of self-inflicted nail gun injuries is lower in comparison to deliberate self-harm (4). Albeit, there was a higher incidence of penetrating brain injury in self-inflicted suicidal attempts. (4, 5, 11) Distinguishing accidental vs non-accidental penetrating nail gun injuries is vital. This identifies concomitant psychiatric disorder(s) in patients

presenting with non-accidental nail gun injuries (10). Litvack et al. reported that more than 65% of intracranial nail gun injury were due to suicidal attempts with elements of psychiatric disturbances (5).

Shape, configuration and trajectory of these embedded nails from simple radiographs allow early deduction of the mechanism of injury and organ of involved. Standard industrial grade nails have a diameter of 15-23 gauge. The length of these nails is approximately  $\frac{3}{8}$  to 2.5 inches long. Bent nails often suggest accidental nail gun discharges due to ricochet, whereas injury from a straight nail could point towards the possibility of mid-air accidental firing. Simple radiographs showing the depth of nail penetration may depict the nature of injury. Deeper nails may represent a purely accidental injury in which the penetration of nail at full force that could not be avoided. However, for nails with superficial or partial penetration, this may be due to a failed attempt at self-inflicted injuries (9-11). As shown in the current case, this gentleman had allegedly attempted suicide by shooting himself with a nail gun. The extraction of four straight nails from different body locations matched the description of a suicidal attempt. Makoshi et al. (4) and Litvack et al. (5) had reported self-inflicted nail gun injury from persons with underlying depression and schizophrenia, as shown in table 1.

In this case the nail embedded deeply in the corona radiata was removed via frontal craniotomy and under direct supervision by the neurosurgeon. Removal under direct supervision is important as this may cause dislodgement of tamponade on injured vessels that may lead to subsequent intracranial hemorrhage. Similarly, the nail lodged in the anterior chest wall close to the axilla was removed under direct vision to allow identification of possible vessel injury. For the nails which were lodged in the lower anterior abdominal wall, there were two methods which were considered in this situation; first via laparoscopic examination and second option which was performed in this current patient via an explorative laparotomy. Benefits of laparoscopic examination include minimal invasiveness, small incision wounds, ability to directly visualize if there were any peritoneal breach and removal of nails under direct vision, shorter length of stay and reduced painful post-operatively. Laparoscopy however, requires insufflation of carbon dioxide to create a pneumoperitoneum. As removal of the nails from the cranium, thorax and abdomen was done in a single setting, the authors were unable to ascertain cranial injuries after its removal. Hence as a preventive measure to prevent high carbon dioxide levels which may worsen possible intracranial injury, laparoscopic examination was not performed in this patient. The known benefit of explorative laparotomy is that it allows relatively easy access and quickly addresses the need for repair if there are any organ injuries present. Despite this, it produces a large wound and post-operative pain and risk of surgical site infection may be higher. For traumatic penetrating wounds, laparotomy is preferred as it allows direct inspection and immediate repair of the injured organs. However, in blunt injuries,



**Table 1:** Reported nail gun injury cases from other literatures

	No. and site of nail gun injury	Documented psychiatric disorder	Mechanism of injury	Strategies in management of these cases	Outcome	Treatment
<b>Makoshi et al. (4)</b>	4 Sites: cranial	Depression/ schizophrenia	Self-inflicted	Use of vice grip to enable a good grip of the nail head and smooth nail extraction to limit injuries to surrounding structures.	Case 1 and 3: No neurological deficit; Case 2: mild-to-moderate cognitive impairment Case 4: mild gait unsteadiness	Craniotomy, wound debridement and nail extraction using vice grips
<b>Litvack et al. (5)</b>	1 Site: cranial	Flattening of affect	Self-inflicted	Conducting surgery under GA instead of LA would avoid unwanted head movements that would have resulted in catastrophic injury during nail removal -limited left temporal craniotomy was done to control bleeding from the middle meningeal artery	Right abducens nerve palsy	Limited left temporal craniotomy and nail extraction using sterile needle nose plier
<b>Xiang et al. (6)</b>	1 Site: cervical spine	Nil	Self-inflicted	CT angiogram was performed preoperatively to review the nail trajectory. Special instructions for patient to swallow methylene blue reagent to identify esophageal injury	No neurological deficit	Strap muscle dissection and nail extraction
<b>Galano et al. (3)</b>	1 Site: abdomen (entry), lumbar spine (exit)	Nil	Self-inflicted	Rehabilitation significantly improved motor function. The use of transcutaneous electrical nerve stimulation and appropriate pain management to reduce neuropathic pain.	Cauda equina syndrome	Rehabilitation
<b>Luo et al. (7)</b>	2 Sites: cranial	Nil	Accidental	Case 1: the nail position was determined using ultrasound guidance and the nail was pulled out along the entry axis.  Case 2: the nail was left in situ due to restricted access as attempts to remove it will pose potential damage to critical white matter tracts like the internal capsule	Case 1: no neurological deficit  Case 2: right sided hemiplegia	Case 1: craniotomy and nail extraction Case 2: conservative and nail was left in situ at left internal capsule to prevent neural damage
<b>Stephens et al. (12)</b>	1 Site: Abdomen	Nil	Accidental	Exploratory laparotomy was performed to assess the extent of injury.  Cattell Braasch maneuver was performed to access the duodenal injury.	Perforated transverse colon and hemoperitoneum	Bowel repair and hemostasis

initial inspection with minimally invasive laparoscopy to look for breach of peritoneum may pre-emptively limit the necessity from laparotomy which may increase risk of post-operative adhesion and length of stay.

Removal of foreign body under direct supervision allows better safety control to identify surrounding injured structures. This allows early identification and direct repair of the involved surrounding structures. In addition, the usage of a vice grip allows better control in removal of nails which are deeply embedded (9). This allows a firm grip and smooth retrieval rather than sequential removal which may cause damage to surrounding organs. Removal of nails from the cranial vault with injuries to the brain may lead to post-operative seizures, albeit its low incidence of occurring. Anti-epileptics are only recommended if there is evidence of fitting pre or post-operatively with severe brain and white matter injury. As most of these commercially produced nails were packaged without major contamination, prolonged antibiotics were unnecessary to prevent surgical site infection. As the diameter of these nails were small with single entry trajectory, tetanus injection with prophylactic pre-operative antibiotics is suffice to prevent major infections. Despite the dismal and dramatic imaging produced by cranial nail gun injuries, prognosis is good, with majority sustaining minimal to know neurologic deficit post-operatively. This is due to the small diameter of the nail which more than often on removal compresses and seals off possible bleeding risks (10).

Complications of nail gun injuries reported in the literature include neurovascular deficits, functional impairment of the extremities and severe infections post-operatively (Table 1). Despite multiple sites of nail penetration to the brain, axilla and abdomen, none of these injuries had resultant morbidity in this case. Appropriate selection of the imaging modality of choice is important to identify injuries to critical structures. In most cases, a plain radiograph is sufficient to identify the site of injury. Computed tomography may identify suspicious injuries to major vessels and vital organs which may lead to pre-operative planning (13).

### **Conclusion**

As nail guns are becoming more accessible to the public, there have been increasing reports of traumatic nail gun injuries. Prompt identification of self-inflicted nail-gun injuries allow concomitant psychiatric treatment to prevent recurrent of similar injuries. Stable nail-gun injuries may benefit from initial imaging. However in hemodynamically unstable cases, prompt surgical intervention is necessary to prevent exsanguination.

### **What is new in this case report compared to previous literature?**

Incidence of nail gun injuries is increasing and many cases goes unreported in Malaysia. This case report increases the awareness towards nail-gun injuries and its associated complications. Treatment of such deliberate self-harm

requires follow-up with psychiatric team to prevent recurrence of such case.

### **What is the implication to patients?**

Although most of nail gun injuries are trivial, deeply embedded nails with suspected injury to vital organs requires a multidisciplinary approach. This case report increases the awareness of civilians and patients towards the morbidity and potential mortality which is associated with such injuries.

### **Acknowledgements**

Nil.

### **Competing interests**

All the authors have declared no competing conflict of interest.

### **Informed consent**

Written consent was taken from patient.

### **Funding**

Self-funded.

### **References**

1. Salco. The History and Invention of Nail Guns. Available at: <https://www.stapleheadquarters.com/the-history-and-invention-of-nail-guns>. Accessed 23 August 2021.
2. Horne BR, Corley FG. Review of 88 nail gun injuries to the extremities. *Injury*. 2008;39(3):357–61.
3. Galano E, Gélis A, Oujamaa L, Dutray A, Pelissier J, Dupeyron A. An atypical ballistic traumatic cauda equina syndrome with a positive outcome. Focus on prognostic factors. *Ann Phys Rehabil Med*. 2009;52(10):687-93.
4. Makoshi Z, AlKherayf F, Da Silva V, Lesiuk H. Nail gun injuries to the head with minimal neurological consequences: a case series. *J Med Case Rep*. 2016;10:58.
5. Litvack ZN, Hunt MA, Weinstein JS, West GA. Self-inflicted nail-gun injury with 12 cranial penetrations and associated cerebral trauma. Case report and review of the literature. *J Neurosurg*. 2006;104(5):828-34.
6. Xiang G, Wu Z, Zhao X, Zhao X, Feng Y. Nail Gun Injury of the Spine: Case Report and Review of the Literature. *World Neurosurg*. 2019;132:321-5.
7. Luo W, Liu H, Hao S, Zhang Y, Li J, Liu B. Penetrating brain injury caused by nail guns: two case reports and a review of the literature. *Brain Inj*. 2012;26(13-14):1756-62.
8. The National Institute for Occupational Safety and Health (NIOSH). Nail Gun Safety. 2020. Available at:

<https://www.cdc.gov/niosh/topics/nailgun/default.html>. Accessed 23 August 2021.

9. Temple N, Donald C, Skora A, Reed W. Neuroimaging in adult penetrating brain injury: a guide for radiographers. *J Med Radiat Sci.* 2015;62(2):122-31.
10. Wang SH, Chen MY, Yan JL, Huang TY, Chang CC, Chien CY. Survival after multiple nail gun injuries to the brain, lung, and heart: a case report and a review of the literature. *J Int Med Res.* 2021;49(10):3000605211049923.
11. Testerman GM, Dacks LM. Multiple Self-inflicted Nail Gun Head Injury. *South Med J.* 2007;100(6):608–10.
12. Stephens GC, Claydon MH. A case of abdominal trauma. *J Surg Case Rep.* 2015;2015(2):rjv005.
13. Osborn TM, Bell RB, Qaisi W, Long WB. Computed Tomographic Angiography as an Aid to Clinical Decision Making in the Selective Management of Penetrating Injuries to the Neck: A Reduction in the Need for Operative Exploration. *J Trauma.* 2008;64(6):1466–71.