

POSTPARTUM PITUITARY APOPLEXY: A CASE REPORT

Tan CY^{1,2}, and Abu Bakar MA^{1,2}.

¹Department of Emergency Medicine, School of Medical Sciences, Health Campus, Universiti Sains Malaysia, 16150 Kubang Kerian, Kelantan, Malaysia.

²Hospital Universiti Sains Malaysia, Kubang Kerian, Kelantan, Malaysia.

Correspondence:

Mimi Azliha Abu Bakar,
Department of Emergency Medicine,
School of Medical Sciences, Health Campus,
Universiti Sains Malaysia,
16150 Kubang Kerian, Kelantan, Malaysia.
Email: azliha79@usm.my

Abstract

Background: Postpartum pituitary apoplexy is an extremely rare neurological emergency. It may present with sudden onset of headache, vomiting, nausea, and visual disturbances. This potentially life-threatening emergency requires a high index of suspicion from the attending clinician. Postpartum pituitary apoplexy can be challenging to diagnose because of its symptoms that overlap with multiple other conditions. There is a limited number of case reports on postpartum pituitary apoplexy.

Case presentation: We present a case of a 30-year-old multiparous woman with gestational diabetes mellitus who experienced on and off headache from 37 weeks of gestation. Her complaint was not investigated by medical personnel during her routine antenatal follow-ups until after she had a normal delivery. Subsequently, she developed diplopia, nauseated and vomiting episodes post-delivery, but she only came to seek treatment in our emergency department on day 12 postpartum as the symptoms were not resolved. Initial Contrast Enhanced Computed Tomography (CECT) of the brain revealed an enhancing sellar lesion causing widening of pituitary fossa, after which she was scheduled for Magnetic Resonance Imaging (MRI). MRI brain revealed a lobulated sellar and suprasellar mass with a mass effect to optic chiasm and she underwent endoscopic endonasal transsphenoidal excision of the tumour. Post operatively, her vision improved and she was subsequently discharged with oral hormonal supplements.

Conclusion: Diagnosis of pituitary apoplexy should be considered whenever headache and neurological deficits are present, although it is an extremely rare condition.

Keywords: Postpartum, Pituitary Apoplexy, Pituitary Macroadenoma

Introduction

The pituitary gland is an essential structure of the human brain as it has multiple vital functions for sustaining life. It has two distinct regions, the anterior and posterior lobes, located within the sella turcica of the sphenoid bone. The anterior lobe secretes most hormones, and the hypothalamus regulates it. Pars distalis, a part of the anterior pituitary, enlarges during pregnancy, causing to a nearly doubled size of the pituitary gland (1).

Pituitary apoplexy is a neurological emergency which may become a potentially life-threatening disorder caused by haemorrhage or acute ischemic infarction of the pituitary gland. This condition is rare, with an incidence of two to seven per cent (2). Pituitary adenomas are prone to necrosis and bleeding, as tumour expansion causes ischemia and compression of the vessels against the sellar diaphragm or when the tumour outgrows its blood supply. Fragile tumour

vessels may also increase the risk of haemorrhage. Pituitary apoplexy may also occur in non-adenomatous or normal pituitary, especially during pregnancy (3).

Clinical features of pituitary apoplexy vary and are affected by the extent of necrosis, haemorrhage, and oedema. 80% of patients experience a sudden and severe onset of headaches. Other symptoms include impaired visual acuity (52%), visual disturbances (64%), vomiting (69%), and diplopia (78%) (2, 3). Although pituitary apoplexy is a rare case, if left untreated or misdiagnosed, it can lead to serious complications such as permanent visual loss, adrenal insufficiency, hypopituitarism, and even death.

Our objective is to share this uncommon case to foster increased awareness and careful consideration in the treatment of similar patients. Through this, we aim to encourage continuous learning and attentiveness among healthcare professionals.

Case presentation

A thirty-year-old woman, at gravida 4 para 3, started experiencing on and off headaches around 37 weeks of gestation which she described the headaches as occurring daily, bitemporal and frontal in location, throbbing in nature, and relieved by oral paracetamol. Antenatally, she had three previous normal pregnancies without complications, gestational diabetes mellitus on diet control, a history of childhood bronchial asthma, and obesity. During her routine follow-up at a local clinic, her complaint of headaches was not investigated until after she delivered her child. Her peripartum period had no complications, and blood loss was estimated to be about 200 ml. Her pre-delivery haemoglobin was 12.5 g/dl. After delivery, her headaches persisted but relieved by paracetamol. During her post-natal follow-up, the attending team at the local clinic did not proceed with further investigations for her complaint. They thought her complaint was attributed to a lack of rest and sleep.

She decided to seek treatment in our Emergency Department 12 days postpartum, in which she developed new symptoms that gradually worsened her visual disturbances. She also experienced nausea and episodes of vomiting on the day of her visit. Upon examination in the Emergency Department, her cranial nerves and neurological examination were unremarkable except for bitemporal hemianopsia. Contrast Enhanced Computed Tomography (CECT) of the brain was performed, which revealed a well-defined lesion arising from the sellar region extending to the suprasellar region, measuring 1.0 cm x 1.9 cm x 2.0 cm (AP x W x CC). Some areas of hypodensity were

observed within the lesion, which may represent cystic or necrotic areas (Figure 1).

The impression was of an enhancing sellar lesion causing widening of the pituitary fossa, which likely representing a pituitary macroadenoma. Then, it proceeded with neurosurgical consultation in which Magnetic Resonance Imaging (MRI) of the brain was arranged. The MRI revealed a well-defined lobulated mass arising from the sellar region, extending superiorly involving the suprasellar region, measuring 1.1 cm x 1.8 cm x 2.1 cm (AP x W x CC), with mass effect and compression onto optic chiasm, displacing it superiorly (Figure 2). Ophthalmology consult also revealed findings tally to the imaging (Figure 3 and Figure 4). Initially, laboratory results showed an elevated prolactin level (1416 mIU/L), but low levels of thyroxine (4.42 pmol/L), luteinizing hormone (< 0.1 IU/L), and cortisol (6.26 nmol/L). Other hormones parameters were normal e.g., follicular stimulating hormone (1.6 IU/L) and thyroid stimulating hormone (0.782 mIU/ml). She was started on oral levothyroxine 100 mcg daily with hydrocortisone taper.

Surgical intervention was pursued, in which she underwent endoscopic endonasal transsphenoidal excision of the tumour. Intra-operatively, the presence of a gush of old clots and the tumour was debulked. A histopathology consultation showed the presence of a pituitary tumour. Post-operatively, she was treated for cranial diabetes insipidus which was started on desmopressin and continued on oral thyroxine and hydrocortisone. Upon discharge, her neurological examination was unremarkable with no residual oculomotor paresis.

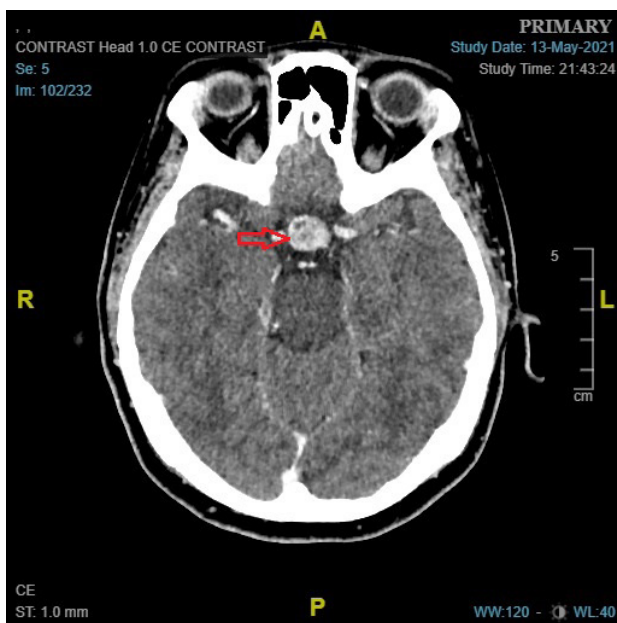


Figure 1: CECT of the brain revealed an enhancing sellar to suprasellar lesion causing widening of pituitary fossa (Red arrow)

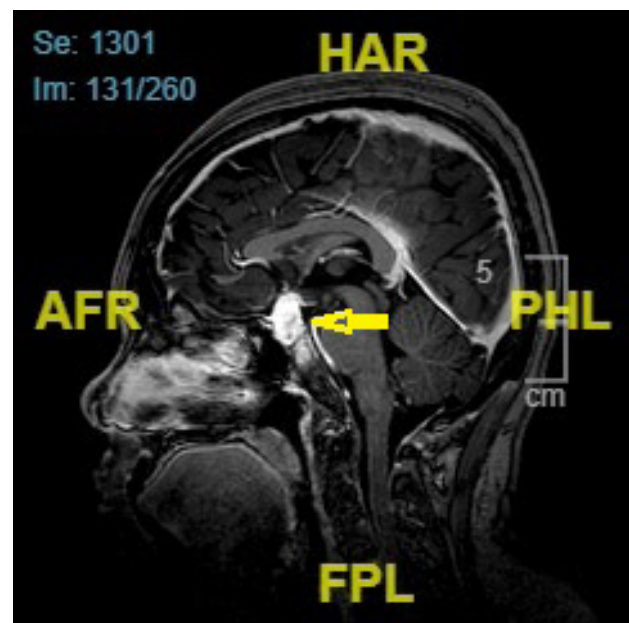


Figure 2: T1-weighted Magnetic Resonance Brain (MRI) of the brain revealed a lobulated pituitary macroadenoma with suprasellar extension (Yellow arrow)

Single Field Analysis

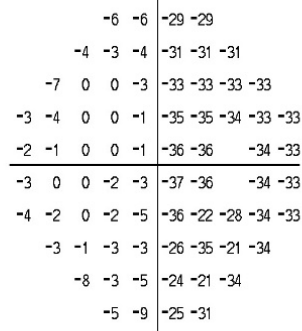
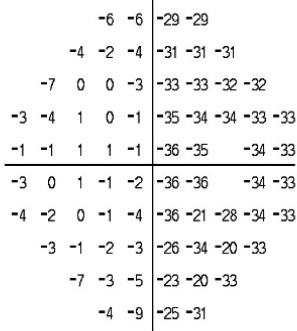
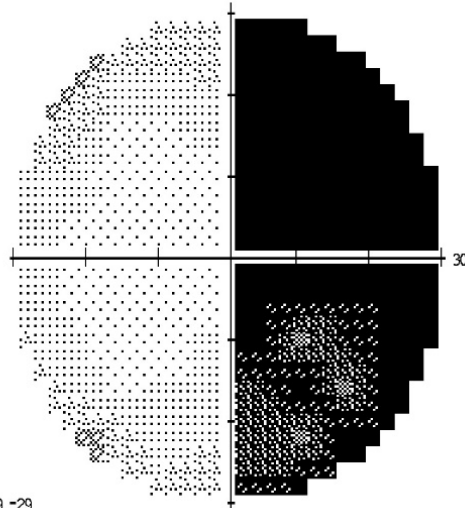
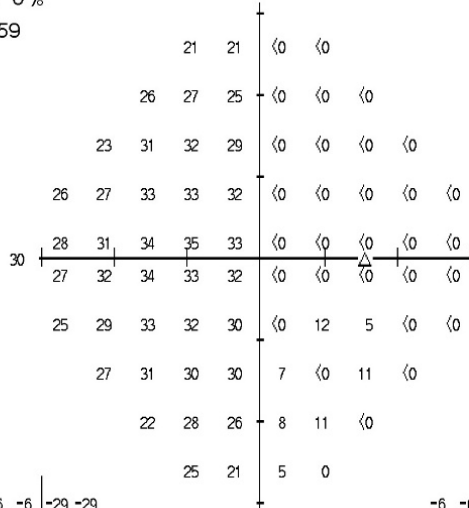
Eye: Right

Name: ██████████	DOB: 26-12-1990
ID: B██████	

Central 30-2 Threshold Test

Fixation Monitor: Blind Spot Stimulus: III, White Pupil Diameter: Date: 17-05-2021
 Fixation Target: Central Background: 31.5 ASB Visual Acuity: Time: 9:52 AM
 Fixation Losses: 0/12 Strategy: SITA-Fast RX: DS DC X Age: 30
 False POS Errors: 0 %
 False NEG Errors: 0 %
 Test Duration: 05:59

Fovea: <0 dB ■



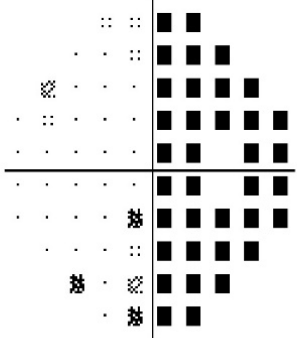
GHT
Outside Normal Limits

VFI 54%

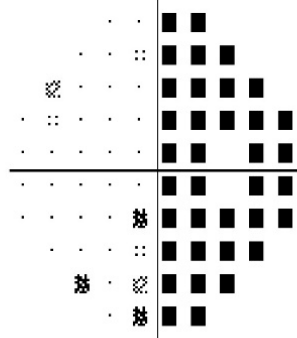
MD -14.58 dB P < 0.5%

PSD 17.02 dB P < 0.5%

Total Deviation



Pattern Deviation



∴ < 5%
 ⊗ < 2%
 ⊠ < 1%
 ■ < 0.5%

KLINIK PAKAR OFTALMOLOGI
 HOSPITAL UNIVERSITI SAINS MALAYSIA
 USM KAMPUS KESIHATAN
 16150 KUBANG KERIAN
 KELANTAN DARUL NAIM

Figure 3: Right visual field test showed bitemporal hemianopsia

Discussion

An American neurologist, Pearce Bailey, first discovered pituitary tumour-associated haemorrhage in 1898 (4). However, the term “pituitary apoplexy”, referring to both bleeding and necrosis in a pituitary tumour, was used by Brougham et al. in 1950 (5).

Most of the patients presented with clinical features of pituitary apoplexy usually have a pre-existing pituitary adenoma, however most are unaware of the lesion (6). The condition mostly occurs spontaneously, with about 10-40% of cases having identifiable precipitating factors (7). There are several factors that can precipitate the condition which include endocrine stimulation tests, cabergoline treatment, pituitary irradiation, anticoagulated states, thrombocytopenia, and pregnancy (6, 7).

Sheehan syndrome is another cause of hypopituitarism that occurs postpartum. Sheehan syndrome occurs when there is necrosis of the pituitary gland secondary to ischemia following significant blood loss during childbirth. Clinical features such as adrenal insufficiency, hypothyroidism, and hypopituitarism may be present, though visual changes are rare. This condition is not included as pituitary apoplexy, as patients do not have a pre-existing tumour (6).

The reported incidence of apoplexy in pituitary adenoma is rare. It is estimated at 0.2% annually. Tumours larger than 10 cm and those that are rapidly growing are at greater risk (6). It was reported about 60-80% of cases presented with pituitary apoplexy in previously unknown pituitary adenoma (8).

Diagnosing gestational or postpartum pituitary apoplexy is as challenging as it sounds. Most of the patients do not have any pituitary history. Most patients will experience headaches which are also associated with various pathological conditions. In addition, symptoms such as blurring of vision, diplopia, photophobia, or bitemporal hemianopsia vision have been reported (9). An increase in pituitary size will raise intrasellar pressure, causing compression and necrosis of the pituitary gland, leading to pituitary insufficiency. Patients with pituitary apoplexy may exhibit neurological symptoms related to increased intracranial pressure and in severe cases, even loss of consciousness. Given that multiple neurological conditions may have similar presentation, a high index of suspicion should be prompted to investigate for pituitary apoplexy (9). It is imperative for clinicians practicing in Mother and Child Healthcare facilities or in outpatient departments to maintain a heightened awareness regarding pituitary apoplexy, as it is a rare diagnosis that requires immediate recognition and referral to avoid the possibility of severe complications, such as acute central hypoadrenalism and neuro-ophthalmologic deficits (10).

Pertaining to the case scenario, a CECT of the brain was sought first instead of an MRI of the brain in the emergency department due to several factors. First, the patient seek treatment after office hours in which our hospital's MRI service was unavailable during the time of request.

Furthermore, CT scan is available with minimal waiting time and costs less than MRI scan.

Conclusions

Pituitary apoplexy in pregnant and post-partum patients is a rare cause of sudden headaches with severe neurological and endocrine sequelae. It can be due to hemorrhage or infarction of the pituitary gland. Despite other conditions need to be ruled out for patients presenting with similar symptoms, the diagnosis of pituitary apoplexy need to be considered as a differential diagnosis by treating clinicians, especially in Mother and Child Healthcare Clinics. Early recognition and referral may prevent unwanted sequelae of neuroendocrine emergencies or irreversible neuro-ophthalmological deficits.

Acknowledgement

We would like to thank our Hospital Director for allowing us to publish this case study.

Competing interest

The authors declare no conflicts of interest.

Financial support

None.

Ethical Clearance and Informed consent

The authors are accountable for all aspects of the work in ensuring that questions related to the accuracy or integrity of any part of the work are appropriately investigated and resolved. All procedures performed in this study were in accordance with the ethical standards of the institutional and/or national research committee(s) and with the Helsinki Declaration (as revised in 2013). Verbal consent was obtained from the patient for publication of this case report and accompanying images before the preparation of the case report. Written consent was not able to be obtained due to logistical difficulties.

References

1. Ganapathy MK, Tadi P. Anatomy, Head and Neck, Pituitary Gland. In StatPearls, StatPearls Publishing. 2023.
2. Salehi N, Firek A, Munir I. Pituitary Apoplexy Presenting as Ophthalmoplegia and Altered Level of Consciousness without Headache. Case Rep Endocrinol. 2018; 2018:7124364.
3. Watson V. An unexpected headache: pituitary apoplexy in a pregnant woman on anticoagulation. BMJ Case Rep. 2015; 2015:bcr2015210198.
4. Bailey P. Pathological report of a case of acromegaly with especial reference to the lesions in the hypophysis cerebri and in the thyroid gland; and a case of hemorrhage into the pituitary. Philadelphia Medical Journal. 1898; 1:789-792

5. Brougham M, Heusner AP, Adams RD. Acute degenerative changes in adenomas of the pituitary body--with special reference to pituitary apoplexy. *J Neurosurg.* 1950; 7(5):421-439.
6. Mayol Del Valle M, De Jesus O. Pituitary Apoplexy. In *StatPearls.* StatPearls Publishing. 2023.
7. Bouirig K, Benkirane R, Amazouzi A, Boutimzine N, Cherkaoui LO. Post-Partum Pituitary Apoplexy: A Case Report. *Austin J of Clin Ophthalmol.* 2023; 10(1):1139.
8. Jemel M, Kandara H, Riahi M, Gharbi R, Nagi S, Kamoun I. Gestational pituitary apoplexy: Case series and review of the literature. *J Gynecol Obstet Hum Reprod.* 2019; 48(10):873-881.
9. Pop LG, Ilian A, Georgescu T, Bacalbasa N, Balescu I, Toader OD. Pituitary adenoma apoplexy in pregnancy: Case report and literature review. *Exp Ther Med.* 2022; 23(3):218.
10. Geissler F, Hoesli I, Todesco Bernasconi M. Recurrent pituitary apoplexy in pregnancy. *BMJ Case Rep.* 2021; 14(8):e242353.